

## The Healing Effect of a Topical Mixture of Apricot Seeds and Curcumin on Second Degree Burn Wounds in Rat

Doaa T. Gebreel<sup>1</sup>, Nevien M. Ahmed<sup>2</sup>, Eman A. Youssef<sup>3</sup>

<sup>1</sup>(Department of Medical Equipment Technology, Faculty of Allied Medical Science/ Pharos University in Alexandria, Alexandria, Egypt)

<sup>2</sup>(Department of Biochemistry, Faculty of Dentistry/ Pharos University in Alexandria, Alexandria, Egypt)

<sup>3</sup>(Department of Histochemistry and Cell Biology, Medical Research Institute/ Alexandria University, Egypt  
Corresponding Author: Doaa T. Gebreel

---

**Abstract:** Burns are still considered one of the most disturbing conditions in emergency medicine in developed and developing countries, resulting into physical and psychological scars. This study aimed to assess the effect of the topical mixture of apricot seeds and curcumin on wound healing of burned skin in Wistar rats by evaluating biochemical markers and histo-pathological examinations. Forty two male Wistar rats divided into 6 equal groups. Group I: control group, thirty six rats were subjected to a second degree burn wound. Group II: injured rats, group III: received olive oil, group IV: received nano-curcumin, group V: received nano-apricot seeds and group VI: received a mixture of nano-apricot seeds, curcumin and olive oil twice daily for 3 weeks. Nano-particles of apricot seeds and curcumin were prepared according to precipitation method. Particle sizes, morphology of the desired nano-particles were evaluated at first. At the end of the study, all animals were sacrificed. The serum and wound tissues collected for analyze biochemical, and histo-pathological changes. Topical mixture of nano-apricot seeds and curcumin with narrow particle size within range of 12-50 nm resulted into a decrease in size of the burn wounds and a reduction in inflammation markers, oxidative factors and enhancing anti-oxidative enzymes in comparison with control, apricot seeds or curcumin groups. These results confirmed by biochemical and histo-pathological examinations. The results demonstrate the beneficial effects of the topical application of mixture of nano-apricot seeds, curcumin and olive oil in the acceleration of wound healing as indicated by improved biochemical parameters and also, confirmed by histo-pathological examinations.

---

Date of Submission: 04-11-2019

Date of Acceptance: 20-11-2019

---

### I. Introduction

Burns are still considered one of the most disturbing conditions in medicine affecting all age groups in developed and developing countries.<sup>1</sup> Wound healing is a biological process which involves four main phases including: homeostasis, inflammation, proliferation and maturation which take long duration.<sup>2</sup> Various factors contribute to delay the wound repair process such as oxygen free radicals. Oxidative stress plays an important role to delay healing and contributes to tissue damage.<sup>3</sup> Burns are sometimes associated with chronic mono – or poly microbial biofilm infections and are characterized by tolerance and resistance to antimicrobials.<sup>4</sup> Nano-biomaterials are promising therapeutic strategy for skin wound healing.<sup>5</sup> As the proposed nanosystem including a variety of nano-materials is able to avoid chronic microbial contamination of the wound and also inhibit/disrupt the biofilms that usually form at the site of wounds and delay significantly the healing chances. Nanoparticles and nano-structured coatings can be active at low concentrations toward a large variety of infectious agents; thus, they are unlikely to elicit emergence of resistance.<sup>6</sup>

For centuries, the beneficial plants have been commonly utilized in wound healing of burned injuries.<sup>7</sup> Natural products are most likely going to continue to play a role in health care and become even more valuable as sources of new drug. Natural compounds comprise a wide variety of chemical substances, each with its specific properties and particular place in the wound-healing process.

Apricot (*Prunus armeniaca* L) is a tree classified under Rosaceae family and is mainly cultivated in North Africa, Asian countries, and America.<sup>8</sup> It has been used in folk medicine as a remedy for various diseases as gastric inflammations and dermatitis.<sup>9</sup> Apricot seeds are a good dietary source of oil, phenolic compounds, protein and fiber.<sup>10</sup> Oleic acid and linoleic acid are the major components of the oil portion and pectin polysaccharides. The oil has also been used in cosmetics and as a pharmaceutical agent.<sup>11</sup> Several studies have also shown antioxidant and radical scavenging properties, antimicrobial activity for apricot seeds.<sup>12</sup>

Among natural antioxidants, curcumin is one of the most potent anti-inflammatory antioxidant in clinical medicine.<sup>13</sup> Curcumin derived from the plant *Curcuma longa* is a gold-colored Indian spice used not

only for health concern but also for the food preservation. The diferuloyl-methane part of curcumin has antioxidant and anti-inflammatory properties without toxicity even at high doses. Curcumin has direct antioxidant properties mediated by regulation of some enzymes, transcription and growth factors, inflammatory cytokines.<sup>14</sup>

## **II. Material And Methods**

Forty two male Wister rats with a mean weight of 180 to 220 g were used in this study. The rats were obtained from animal house- Pharos University in Alexandria and the study was conducted in the Medical Research Institute. The rats were randomly divided into sex groups, all with an equal number of animals. To create a burn wound in animal, the rats were anesthetized by intraperitoneal injection of ketamine (60 mg/kg) and xylazine (10 mg/kg). After shaving animal's dorsum hair, a deep second degree burn wound was created by a metal cube with dimensions of 2 cm × 3 cm × 1 cm that was heated to 100°C for 15 s and an area of about 6 cm<sup>2</sup> was burned. Thereafter, medication was initiated for five four groups with different materials.<sup>15</sup> During the study period all animals were kept under standard laboratory conditions and were provided with identical food and water. After burn injury, rats were individually housed in separate cages. The cages were cleaned daily and kept free from infectious agents. The rats divided into sex groups. First group: control group. Second group: burned rats did not receive any treatment. Third group: rats received olive oil. Fourth group: rats received nano-curcumin. Fifth group: rats received nano-apricot seeds. Sixth group: received the mixture of nano-apricot seeds and curcumin. Rats treated with equal volume of topical formulations twice daily for 3 weeks with regards to the assigned group until 12 hours before samples collection.

Apricot was purchased from local fruit market (Alexandria, Egypt, 2018). Apricot flesh was removed from fruits; the apricot seeds was washed with tap water and air-dried at 30°C for about 2 weeks the seeds of apricot was cracked manually and stored at -20°C in sealed plastic bags until used and ground in a coffee machine for 1 min.

Curcumin, Poly vinyl alcohol (PVA) and Tween 80 were purchased from Sigma Aldrich CO, Germany.

### **Preparation of Apricot seeds and Curcumin - loaded nanoparticles**

Nano-particles were prepared by precipitation method with modifications,<sup>16</sup> an aqueous phase containing TWEEN80 as stabilizer (80mg of tween80 in 10ml deionized water; 0.80% w/v) was homogenized for 5mins by vortex. Specific amounts of PVA polymer, Apricot, Olive oil and / or curcumin were dissolved in ethanol (5 ml) as the organic phase and stirred for 30 min at 80 °C. Next, organic phase was added drop wise to 10 ml of TWEEN80 solution while stirring. Afterward, organic phase was evaporated overnight and nano-particles were collected by centrifugation at 13000 rpm for 30 min at room temperature and washed twice with deionized water. We investigate the characterization of nano-particles, such as particle size, morphology, Ultraviolet spectrometer measurements, Fourier transform infrared spectroscopy and zeta potential. Particle size and morphology were observed using a Transmission Electron Microscope (JEOL JEM-2100 high resolution TEM at an accelerating voltage of 200 kV). Infrared (IR) absorption spectra of nanoparticles in the wavelength region 4000–800 cm<sup>-1</sup> were recorded using a Fourier transform infrared (FT-IR) spectrometer (TEMSORTM37 – Bruner, USA). The surface charge of the nanoparticles was measured by Zetasizer (Nano ZS, Malvern Inst., Malvern. Worcestershire, UK) using Smoluchowski equation:  $m = \frac{e \cdot z}{h}$  where z is the zeta potential, m is the mobility, e is the dielectric constant, and h is the absolute viscosity of electrolyte solution.<sup>17</sup>

### **Blood samples**

blood samples were collected through cardiac puncture into sterilized plain tubes under light anesthesia using inhaled diethyl ether (Sigma Aldrich, Munich, Germany), and finally animals were decapitated prior to dissection of the wound skin. Skin samples were sectioned into two parts: one part was preserved in 10% formaldehyde and the other was stored at -80C. Blood samples were placed for approximately 1h at ambient temperature to allow clotting and centrifuged at 1 800 g for 15 min at room temperature, then serum samples were separated and preserved at -20C prior to analysis.

### **Inflammatory markers**

Serum inflammatory biomarker levels, comprising tumor necrosis factor alpha (TNF-α), and interleukin (IL)-6 were evaluated using enzyme-linked immunosorbent assay (ELISA) kits (R&D Systems, Minneapolis, MN, USA) according to the manufacturer's instructions.

### **Oxidative stress parameters**

Oxidative stress parameters, including thiobarbituric acid reactive substances (TBARS), superoxide dismutase (SOD) and catalase, were measured in serum using commercially available kits (MyBioSource, San Diego, USA) according to the manufacturer's instructions

### **Histological analyses**

#### **Haematoxylin and eosin stain (H&E):**

For Histopathological investigations, skin tissues from all studied groups were fixed in 10% neutral formalin, dehydrated in ascending series of alcohols, cleared in xylene and then embedded in paraffin wax. Four  $\mu\text{m}$  thick sections were prepared and processed for routinely staining with haematoxylin and eosin.<sup>18</sup>

#### **Masson Trichrome Stain:**

For demonstration of collagen content; 4  $\mu\text{m}$  thick formalin fixed paraffin sections were processed down to distilled water, mordant in Bouin's solution, stained with Weigert's hematoxylin and rinsed in running tap water. Then, sections were stained in Biebrich scarlet-acid fuchsin solution, differentiated in phosphomolybdic phosphotungstic acid solutions, then lastly stained with fast green FCF and processed to be mounted.<sup>19</sup> Stained sections from all studied groups were examined and images were captured using Olympus light microscope – equipped with Spot digital camera and computer program MATLAB software image analyzer in Histochemistry and Cell Biology Department, Medical Research Institute.

### **Statistical Analyses**

Data were fed to the computer and analyzed using IBM SPSS software package version 20.0. Data were fed to the computer and analyzed using IBM SPSS software package version 20.0. (Armonk, NY: IBM Corp). The Kolmogorov-Smirnov, Shapiro and D'Agostino tests were used to verify the normality of distribution of variables, ANOVA was used for comparing the four studied groups and followed by Post Hoc test (Tukey) for pair wise comparison. Significance of the obtained results was judged at the 5% level.<sup>20</sup>

## **III. Result**

### **Particle size and morphology of nanoparticles**

TEM photographs demonstrate the shape and size distributions of the nano-particles. The Apricot nano-particles are spherical in range of 12-20 nm. Figure 1. In TEM images Figure 2, uniformly dispersed Spinal Like-Shape of curcumin with a mean length of 55nm and width of 6 nm. Figure 3 shows the morphology and diameter of the mixture of apricot, curcumin nano-particles and olive oil.

### **UV-VIS Spectra analysis**

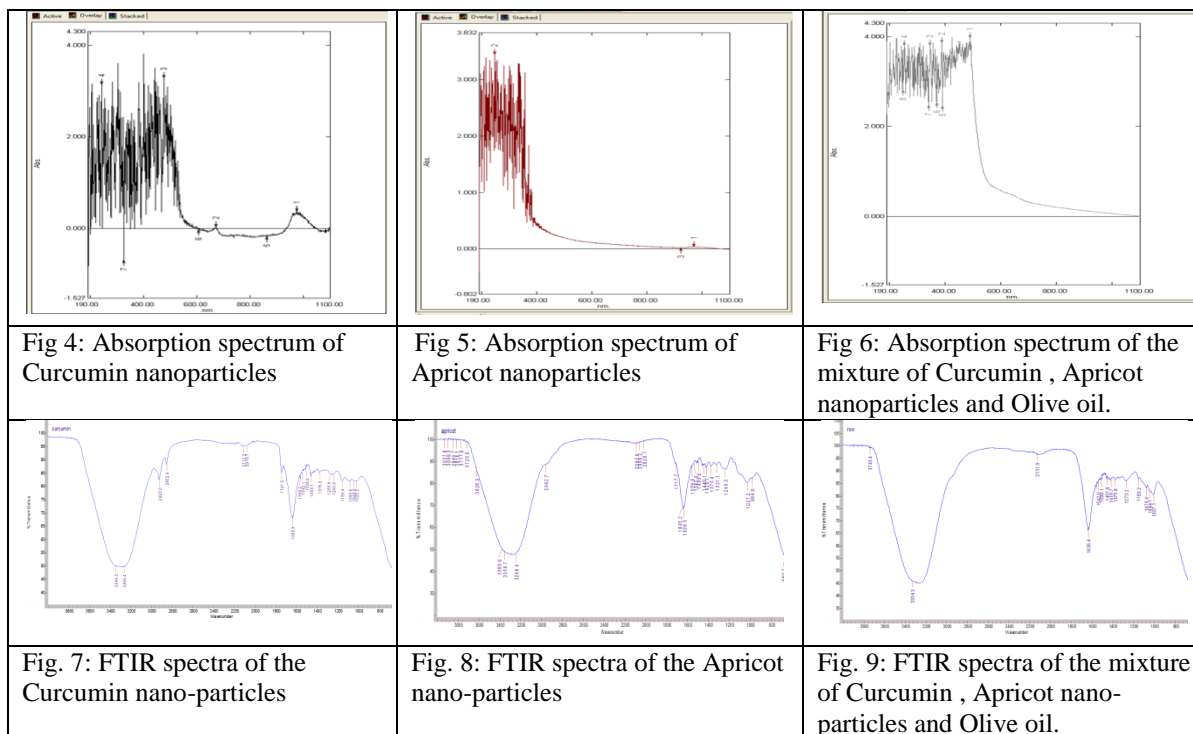

Synthesized of curcumin, apricot nano-particles and mixture of them were confirmed by UV-VIS spectra. Figure 4- 6 The absorption maxima was scanned at the wavelength of 300–1000nm. The maximum absorption ( $\lambda$  max) spectrum of curcumin, apricot nano-particles and mixture of them were observed at 476, 274 and 488 nm respectively.

### **Fourier Transform Infrared (FT-IR) spectral studies:**

FTIR spectra of the curcumin Figure 7, apricot nano-particles Figure 8 and the nano-particles mixture Figure 9 were investigated. The characteristic peaks observed with curcumin, apricot and the mixture indicating that there is no interaction between the nano-particles and there is no effect on the functional groups.

### **Zeta Potential**

The zeta potential of the particular drug carrier systems is a very important parameter that affects the physical stability and in vivo fate of the carriers. The surface charges of the nano-particles were -10.3 mV for Apricot nano-particles, and 9.5mV curcumin nano-particles and - 9.3 mV for the mixture.



### Inflammatory markers and oxidative stress

Mean wound surface area was compared between day 0 and day 21 of treatment, and showed that in rats treated with curcumin, apricot seeds and the mixture of curcumin, apricot seeds and olive oil, wound surface area was significantly reduced at day 21 of treatment compared with first day . Serum TNF- $\alpha$  and IL-6 levels were all significantly increased in the burn injury group compared with uninjured controls. TNF-  $\alpha$ , and IL-6 were significantly lower at day 21 of olive oil, curcumin or apricot seeds compared with injured burned rats (P<0.05). Table 1. Levels of TBARS were significantly higher, and both catalase and SOD levels were significantly lower, in burn injury rats versus uninjured controls (P<0.005) Table 2. At the end of treatment with olive oil , curcumin or apricot seeds was associated with significantly lower serum TBARS levels versus control group. Treatment with olive oil, curcumin, apricot seeds and mixture for 3 weeks following burn injury significantly increased SOD and catalase activities versus control group (P<0.01) Table 2.

**Table (1):** Comparison between the six studied groups according to inflammatory markers

	Group 1	Group 2	Group 3	Group 4	Group 5	Group 6	F	p
TNF- $\alpha$ (pg/ml)	141 $\pm$ 8.5	193.2 <sup>a</sup> $\pm$ 12.3	166.8 <sup>ab</sup> $\pm$ 8.3	153.8 <sup>b</sup> $\pm$ 14.1	150.7 <sup>b</sup> $\pm$ 10.8	137.3 <sup>b</sup> $\pm$ 15	18.164*	<0.001*
IL-6 (pg/ml)	138.5 $\pm$ 12.9	191 <sup>a</sup> $\pm$ 12.4	168.3 <sup>ab</sup> $\pm$ 9.0	156.7 <sup>ab</sup> $\pm$ 7.8	154.8 <sup>b</sup> $\pm$ 8.8	141.8 <sup>b</sup> $\pm$ 8.4	21.822*	<0.001*

F: F for ANOVA test

p: p value for comparing between the studied groups

\*: Statistically significant at p  $\leq$  0.05

a: significant with control group

b: significant with injured burns rats (group 2)

**Table (2):** Comparison between the six studied groups according to oxidative stress parameters

	Group 1	Group 2	Group 3	Group 4	Group 5	Group 6	F	p
TBARS (nmol/ml)	3.3±1.3	8.5 <sup>a</sup> ±0.6	6.6 <sup>ab</sup> ±1.2	6.1 <sup>ab</sup> ±0.5	5.8 <sup>ab</sup> ±0.4	3.9 <sup>b</sup> ±0.9	27.965 <sup>*</sup>	<0.001 <sup>*</sup>
SOD (U/ml)	10.1±1.2	5.6 <sup>a</sup> ±0.7	6.6 <sup>a</sup> ±0.6	7.1 <sup>a</sup> ±0.9	8.0 <sup>ab</sup> ±1.3	9.6 <sup>b</sup> ±1.1	18.875 <sup>*</sup>	<0.001 <sup>*</sup>
Catalase (nmol/ml)	76.3±7.5	40.8 <sup>a</sup> ±2.8	57 <sup>ab</sup> ±3.7	63.8 <sup>b</sup> ±11.4	68.7 <sup>b</sup> ±9.5	78.8 <sup>b</sup> ±8.7	18.840	<0.001 <sup>*</sup>

F: F for ANOVA test

p: p value for comparing between the studied groups

\*: Statistically significant at  $p \leq 0.05$

a: significant with control group

b: significant with injured burns rats (group 2)

### Histopathological results:

Histopathological changes in skin cross sections, of all studied groups, stained with H&E were seen in Figure 10. Sections from rats of normal group showed patent architecture of intact skin; well defined epidermis with its layers {stratum granulosum, stratum spinosum and stratum germinativum} and dermis containing hair follicles (A&B). Complete destruction of skin most clearly in the epidermis and dermis in burned skin sections as seen in control group (C& D). Signs of wound healing as neovascularization and beginning of re-epithelialization were noticed in curcumin group (E&F) as well as seen in apricot group (G & H). Complete epidermal epithelialization and increased fibrosis in dermis of sections from group treated with of curcumin and apricot (I& J). Figure 11.

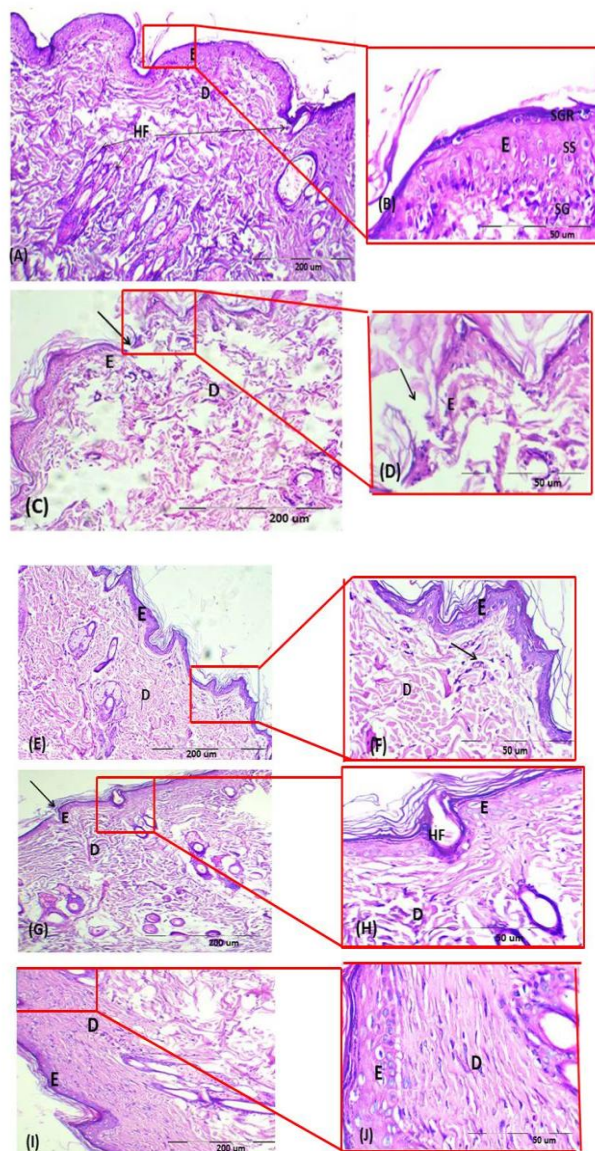


Figure 10: Photomicrographs of skin sections stained with H&E displaying the histopathological changes (Scale bar= 200 & 50 µm). Normal group [A&B]: showing patent architecture of intact skin; well defined epidermis (E) with layers {stratum granulosum (SGR), stratum spinosum and stratum germinativum (SG)}, dermis (D) and hair follicles (HF), control group [C& D]: showing complete destruction of skin (↑), most clearly in the epidermal (E) and dermal (D) sectors, curcumin group [E&F]: showing signs of wound healing as neovascularization (↑) and Beginning of re-epithelialization, apricot group [G & H]: showing beginning of re-epithelialization at wound edge (↑) and curcumin + apricot group [I& J]: showing complete epidermal epithelialization and increased fibrosis in dermis (D).

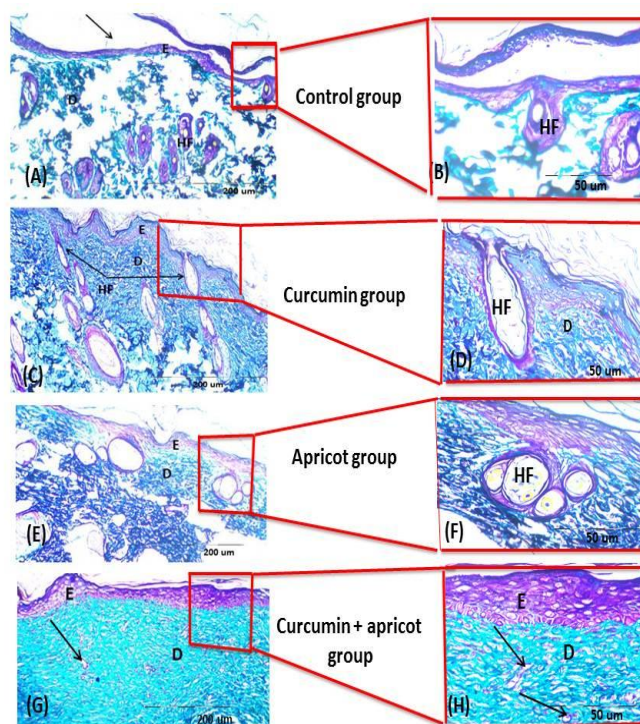


Figure 11: Photomicrographs of skin sections stained with Masson's trichrome stain demonstrating collagen deposition in blue color (Scale bar= 200 & 50 µm). Control group [A & B]: showing reduced collagen fibers in dermis (D) and moderate collagen deposition in dermis (D) in either curcumin [C&D] or apricot [E&F] groups. Note: increased collagenous bundles and many blood vessels (↑) in dermis (D) of curcumin + apricot group [G&H]

#### IV. Discussion

The above data represents a promising therapeutic strategy to treat and accelerate wound healing. Surface morphological features, surface charge, particle size and functional groups were confirmed by TEM, FT-IR, and UV and Zetasizer measurements.

Metabolic variations through oxidative procedures are strongly related to burn injury of the skin, where free radicals are generated via common biological pathways.<sup>21</sup> Difference in the production of free radicals following utilize of antioxidants appears to play a major role in the healing of burn wounds.<sup>22</sup>

The present study demonstrated that burn injury of the skin resulted in oxidative stress and increased serum pro-inflammatory biomarkers. Also indicated that apricot seeds were capable of reducing the effects of burn injury, shown by significant reduction in serum TBARS levels, and increased antioxidant enzymes as catalase and SOD levels compared with untreated controls. It has been shown that low levels of antioxidants accompanied by raised levels of markers of free radical damage play a significant role in delaying wound healing, that ROS produced in response to coetaneous injury impede the healing process by causing damage to cellular membranes, DNA, proteins, and lipids, and that antioxidants promote wound healing.<sup>22</sup> The burn-associated increased inflammatory markers, which play a critical role in burn injury, were also decreased by treatment with apricot seeds with best result with the mixture (Table 1). Singh et al 2002<sup>23</sup> have demonstrated that inflammatory markers such as IL-1 and TNF-a are released by tissue macrophages and monocytes in response to any noxious event, Similarly, serum TNF-a levels were increased in burned animals in the present study, suggesting that amelioration of burn associated oxidative injuries by apricot seeds and curcumin may involve inhibition of a wide range of pro-inflammatory mediators generated by leukocytes and macrophages.

The present data showed that oxidative stress was induced during 3 weeks following burn injury in rats (Table 2). These results concur with other studies reporting increased lipid peroxidation within 2 weeks following burn injuries and decreased antioxidant enzyme activities associated with a disturbance in the microcirculation, exhaustion of the antioxidant system, and oxidative stress.<sup>24</sup> Our result is consistent with that obtained by Cetinkale et al (1999)<sup>25</sup> who demonstrated that antioxidants had a positive effect on immune function and that ROS contributed, in part, to burn-mediated immune suppression. In Eastern medicine, bitter apricot seed (*Semen Armeniacae amarum*) has been traditionally used to treat skin diseases.

Apricot seed is a unique biochemical structure rich in iron, potassium, phosphorus, amygdaline, vitamin B17. It has anti-oxidant, anti-inflammatory, anti-viral, immune stimulant carcinocidal activities, anti-angiogenesis and tumor invasion and metastasis. In Eastern medicine, bitter apricot seed (*Semen Armeniacae amarum*) has been traditionally used to treat skin diseases.<sup>26</sup> Parlakpinar et al.(2009)<sup>27</sup> also reported the cardioprotective activity of apricot in rats and attributed that activity to the presence of antioxidant phenolic compounds, Apricot kernel appeared to be an important natural antioxidant source like tocopherols and phenolic compounds.<sup>28</sup>

Phenolic compounds are the main antioxidants found in virgin olive oil, a well characterized oil known for its health benefits. These compounds are very important for the oxidative stability of the PUFAs within the oil. The main phenolic subclasses present in olive oil are phenolic alcohols, phenolic acids, flavonoids, lignans, and secoiridoids.<sup>29</sup>

Many of properties of curcumin are through the regulation of various transcription and growth factors, inflammatory cytokines, protein kinases, and several enzymes. Curcumin protects skin by quenching free radicals and reduces inflammation through inhibition of nuclear factor-B. It accelerates wound healing, improves collagen deposition and increases fibroblast and vascular density in wounds enhancing. It induces transforming growth factor beta and stimulates angiogenesis and accumulation of extracellular matrix which continues through the remodeling phase of wound repair.<sup>30</sup>

## V. Conclusion

The results clearly demonstrate the beneficial effects of the topical application of mixture of nano-apricot seeds and curcumin in the acceleration of wound healing as indicated by improved biochemical parameters and also, confirmed by histo-pathological examinations.

## Conflicts of Interest

\*The authors declare that they have no conflicts of interest.

## Acknowledgments

This work was supported by Medical Research Institute. Department of Biochemistry and Histochemistry and Cell Biology

## References

- [1]. Akbari H, Fatemi MJ, Iranpour M, Khodarahmi A, Baghaee M, Pedram MS, et al. The healing effect of nettle extracts on second degree burn wounds. *World J Plast Surg*; 2015; 4(1): 23-28.
- [2]. Garraud O, Hozzein WN, Badr G. Wound healing: Time to look for intelligent, 'natural' immunological approaches? *BMC Immunol*. 2017; 18(Suppl 1):23.
- [3]. Parihar A, Parihar MS, Milner S, Bhat S. Oxidative stress and anti-oxidative mobilization in burn injury. *Burns*. 2008;34: 6–17
- [4]. Mara M, Madalina P, Iulia L, Monica C G, Mircea I P and Alina M H. Nanocoatings for Chronic Wound Repair—Modulation of Microbial Colonization and Biofilm Formation. *Int. J. Mol. Sci.*, 2018; 19, 1179.
- [5]. Solmaz G, Faezeh A, Seyed M R S, Sepideh A B, Seyyedeh E M, Setareh H, et al. Nanotechnology in Wound Healing; Semisolid Dosage Forms Containing Curcumin-Ampicillin Solid Lipid Nanoparticles, in-Vitro, Ex-Vivo and in-Vivo Characteristics. *Adv Pharm Bull*. 2018; 8(1): 1-6.
- [6]. Devi N and, Dutta J. Preparation and characterization of chitosan-bentonite nanocomposite films for wound healing application. *Int J Biol Macromol*. 2017 ; 27
- [7]. Li Zhou, Yuewei Xi, Yumeng Xue, Min Wang, Yanle Liu, Yi Guo, and Bo Lei. 2019. Injectable Self-Healing Antibacterial Bioactive Polypeptide-Based Hybrid Nanosystems for Efficiently Treating Multidrug Resistant Infection, Skin-Tumor Therapy, and Enhancing Wound Healing. *Adv. Funct. Mater*. 2019; 29:1-11.

- [8]. Gokhandurmaz MA. Antioxidant properties of roasted apricot (*Prunus armeniaca* L.) kernel. *Food Chem.*2007; 100:1177–1181.
- [9]. Yiğit DD, Yiğit N, Mavi A. Antioxidant and antimicrobial activities of bitter and sweet apricot (*Prunus armeniaca* L.) kernels. *Braz J Med Biol Res.* 2009; 42:346–352.
- [10]. Sefer F, Misirli A, Gulcan R. A research on phenolic and cyanogenic compounds in sweet and bitter apricot kernels. *Proceedings of XII international symposium on apricot culture and decline, ISHS Acta Hort.* 2006; 701:167–170.
- [11]. Ruiz D, Egea J, Gil MI, Tomas-Barberan FA. Phytonutrient content in new apricot (*Prunus armeniaca* L.) varieties. *Acta Horticulturae.* 2006; 717: 363-365.
- [12]. Dragovic-Uzelac V, Delonga K, Levaj B, Djakovic S, Pospisil J. (2005). Phenolic profiles of raw apricots, pumpkins, and their purees in the evaluation of apricot nectar and jam authenticity. *J Agric Food Chem.* 2005; 53: 4836-4842.
- [13]. Kulac M, Aktas C, Tulubas F, Uygur R, Kanter M, Erboga M, Ceber M, Topcu B, Ozen OA. The effects of topical treatment with curcumin on burn wound healing in rats. *J Mol Histol.* 2013; 44:83–90.
- [14]. Haghghi Rabbani N, Naghsh N, Mehrabani D. The protective effect of curcuma longa in thioacetamide-induced hepatic injury in rat. *Global J Pharmacol.* 2013; 7:203–7.
- [15]. Cai EZ, Ang CH, Raju A, et al. Creation of consistent burn wounds: a rat model. *Arch Plast Surg.* 2014;41(4):317-24.
- [16]. Fatemeh Madani, Seyedeh Sara Esnaashari, Basil Mujokoro, Farid Dorkoosh, Masood Khosravani1, Mahdi Adabi. Investigation of Effective Parameters on Size of Paclitaxel Loaded PLGA Nanoparticles. *Adv Pharm Bull.* 2018; (8):1-8.
- [17]. Bayindir-Sezgin, Z., Yuksel, N. “Characterization niosomes prepared with various nonionic surfactants for paclitaxel oral delivery” *J. Pharm. Sci.*2010; 99, 2049-2060.
- [18]. Bancroft, D.J., and Stevens, A. *Theory and Practice of Histology Technique.* 4th ed. Churchill Livingstone, Edinburgh, London, New York.2002; pp116-117.
- [19]. Suvik, A., Effendy, A.W.M. The use of modified Masson’s Trichrome Staining in collagen evaluation in wound healing study. *Malaysian Journal of Veterinary Research.* 2012; 3: 39-47.
- [20]. Kirkpatrick LA, Feeney BC. *A simple guide to IBM SPSS statistics for version 20.0.* Student ed. Belmont, Calif.: Wadsworth, Cengage Learning.2013.
- [21]. Al-Jawad FH, Sahib AS, Al-Kaisy AA. Role of antioxidants in the treatment of burn lesions. *Ann Burns Fire Disasters.* 2008; 21: 186–191
- [22]. Gupta A, Singh RL, Raghubir R. Antioxidant status during cutaneous wound healing in immunocompromised rats. *Mol Cell Biochem.* 2002; 241:1–7.
- [23]. Singh RP and Agarwal R. Flavonoid antioxidant silymarin and skin cancer. *Antioxid Redox Signal.* 2002; 4: 655–663.
- [24]. Dubinina EE. The role of reactive oxygen species as signal molecules in tissue metabolism in oxidative stress. *Vopr Med Khim.* 2001; 47: 561–581.
- [25]. Cetinkale O, Senel O, Bulan R. The effect of antioxidant therapy on cell-mediated immunity following burn injury in an animal model. *Burns.*1999; 25:113–8.
- [26]. Li, K.; Yang, W.; Li, Z.; Jia, W.; Li, J.; Zhang, P.; Xiao, T. Bitter apricot essential oil induces apoptosis of human HaCaT keratinocytes. *Int. Immunopharmacol.* 2016.; 34, 189–198.
- [27]. Parlakpınar H, Olmez E, Acet A, Ozturk F, Tasdemir S, Ates B, et al. Beneficial effects of apricot-feeding on myocardial ischemia-reperfusion injury in rats. *Food Chem Toxicol.* 2009.; 47:802-8
- [28]. Durmaz G, and Alpaslan M. Antioxidant properties of roasted apricot (*Prunus armeniaca* L.) kernel. *Food Chem.* 2007; 100:1177-81.
- [29]. Servili, M.; Esposito, S.; Fabiani, R.; Urbani, S.; Taticchi, A.; Mariucci, F.; et al. Phenolic compounds in olive oil: Antioxidant, health and organoleptic activities according to their chemical structure. *Inflammopharmacology.*2009; 17, 76–84.
- [30]. Shishodia S, Singh T, Chaturvedi MM. Modulation of transcription factors by curcumin. *Adv Exp Med Biol.* 2007; 595:127-48.

Doaa T. Gebreel. " The Healing Effect of a Topical Mixture of Apricot Seeds and Curcumin on Second Degree Burn Wounds in Rat." *IOSR Journal of Biotechnology and Biochemistry (IOSR-JBB)* 5.6 (2019): 26-33.